

Case Report**Hemolacria and More: Spectacular Case of Bleeding in Two Calves**

Songul Erdoğan^{1*}, Hasan Erdoğan¹, Kerem Ural¹, Ismail Günal¹,
Tahir Özalp¹

¹Adnan Menderes University, Faculty of Veterinary, Department of Internal Medicine, Isikli, Aydın, Türkiye

ORCID: 0000-0002-7833-5519

¹Adnan Menderes University, Faculty of Veterinary, Department of Internal Medicine, Isikli, Aydın, Türkiye

ORCID: 0000-0001-5141-5108

¹Adnan Menderes University, Faculty of Veterinary, Department of Internal Medicine, Isikli, Aydın, Türkiye

ORCID: 0000-0003-1867-7143

¹Adnan Menderes University, Faculty of Veterinary, Department of Internal Medicine, Isikli, Aydın, Türkiye

ORCID: 0000-0003-3679-4132

¹Adnan Menderes University, Faculty of Veterinary, Department of Internal Medicine, Isikli, Aydın, Türkiye

ORCID: 0000-0002-9873-0364

Corresponce

Adnan Menderes University, Faculty of Veterinary, Department of Internal Medicine, Isikli, Aydın, Türkiye, +90 256 220 60 00

E- mail: songul.toplu@adu.edu.tr

Doi: 10.5281/zenodo.7486041

Abstract

A 20-day old calf was presented to the Adnan Menderes University, Veterinary Hospital, Department of Internal Medicine and less than one month old calf in the field was reported by the Veterinary Surgeon at different times in 2017 from different farms to Umurlu district. On arrival the present one case presented fever, tachycardia, tachypnea, anormal bleeding symptoms [hemolacria (bloody tears), epistaxis, ear bleeding, prolonged bleeding time following injection and recurrent bleeding all over the body after minor trauma or spontaneously] and the others had an spontaneously bleeding on injection side. As being informed by the owner of both calves there was no change after the treatment performed by initial Veterinary Surgeon for two weeks. In an attempt to determine alterations that might be related to probable bovine neonatal pancytopenia (BNP), blood gas analysis, selected coagulation parameters were analyzed. Only in the first case, performed both rapid ELISA test kit (IDEXX SNAP ® BVDV AntigenTest, United States) and PCR (Veterinary Research Control Institute, Bornova, İzmir) tested for bovine virus diarrhea virus antigen that were all negative. According to blood gas analysis of first case, Hct (<10%), Na⁺ (130.2 mmol/L), K⁺⁺ (4.03 mmol/L), iCa (1.21 mmol/L), HCO₃ (32.8 mmol/L), BE (+6.5 mmol) and coagulation parameter in both cases PT (>101 sec) and fibrinogen (> 113 mg/dL) as well as APTT (64.1 and 67.3 sec) were analyzed respectively. As a result of histopathological analysis and postmortem examination of first case, macroscopically petechial hemorrhage on the whole body, linear bleeding in jejunum and microscopically excudate with fibrin, neutrophil and blood in intestinal villus, tonsillar crypt, and pulmonary alveolus were obtained while other case could not be performed. As a result of clinical examination and laboratory results were suspected BNP and this is first reported case of hemolacria in a calf and associated coagulation variations in calves in Egean Region of Turkey.

Keywords: Bleeding, Calf, Coagulation, Hemolacria

Introduction

Bovine Neonatal Pancytopenia (BNP) as known haemorrhagic diathesis, bleeding calf syndrome, blood sweating (Nguyen et al., 2010) is an bleeding syndrome of neonatal calves as a result of trilineage hypoplasia in bone marrow (Friedrich et al., 2009; Pardon et al., 2010) related or unrelated with Bovine Viral Diarrhea Virus vaccination (Demasius et al., 2014). Disease of calves <1 month old has included controversial and still not fully clarified etiopathogenesis as such calves of dams vaccinated with specific BVD vaccine (PregSure® BVD, Pfizer Animal Health) (Sauet-Louis et al., 2012; Lambton

et al., 2012), given vaccinated or birth a calf with BNP dams colostrum to calves in free of BNP farm (Friedrich et al., 2011; Schroter et al., 2011; Bell et al., 2013) that related to alloreactive maternal antibodies destroyed bone marrow cells of colostrum fed calves (Pardon et al., 2011; Bridger et al., 2011; Assad et al., 2012; Kasonta et al., 2012; Bastian, 2011). Additionally genetic factors have still been contraversial in BNP aetiology (Krappmann et al., 2011). Result of trilineage hypoplasia (Friedrich et al., 2009; Pardon et al., 2010) espically trombocytopenia occured that caused anormal bleeding symptoms spontoneously or after injection/surgical ma-

nuplation (Friedrich et al., 2009; Pardon et al., 2010; Bell et al., 2013; Penny et al., 2009).

Different European countries numerous cases, usually a small percentage of calves affected disease however some farms mortality were up to 5%, were noticed with BNP (Pardon et al., 2010; Bastian, 2011; Theron, 2010). And also other countries were confirmed BNP where specific vaccine (PregSure® BVD, Pfizer Animal Health) has not been sold or were withdrawn from market (Bernier Gosselin et al., 2011; Cooper, 2012). In Turkey, this is first reported case of hemolacria reflected prospective BNP and associated coagulation variations in calves.

Case presentation

A 20-day old calf was presented to the Adnan Menderes University, Veterinary Hospital, Department of Internal Medicine and less than one month old calf in the field was reported by the Veterinary Surgeon at different times in 2017 from different farms to Umurlu district. One case presented fever, tachycardia, tachypnea, abnormal bleeding symptoms [hemolacria (bloody tears), epistaxis, ear bleeding, prolonged bleeding time following injection and recurrent bleeding all over the body after minor trauma or spontaneously] (Figure 1) and the other calf only had an spontaneously bleeding on injection side (Figure 2). Before admission, both calves were treated with symptomatic and any clinical improvement were noted.

Calves born normally and fed colostrum within a few hours after birth history was obtained from owners and calves seemed healthy until the last two weeks before being presented to Faculty were stated. Dams of both cases were reported not be vaccinated against BVD but their previous vaccination status is unknown.

Arterial blood gas analysis and selected coagulation parameters were analyzed. ELISA test kit (IDEXX SNAP® BVDV AntigenTest, United States) and PCR (Veterinary Research Control Institute, Bornova, İzmir) performed in diagnostic procedures of probable BNP to excluding from BVD in first calf.



Figure 2. Prolonged bleeding time following injection in case 2

According to blood gas analysis of first case Hct (<10%), Na⁺ (130.2 mmol/L), K⁺ (4.03 mmol/L), iCa (1.21 mmol/L), HCO₃ (32.8 mmol/L), BE (+6.5 mmol) and coagulation parameter in both cases PT (>101 sec) and fibrinogen (> 113 mg/dL) as well as APTT (64.1 and 67.3 sec) were analyzed respectively. As a result of histopathological analysis and post-mortem examination of first case, macroscopically

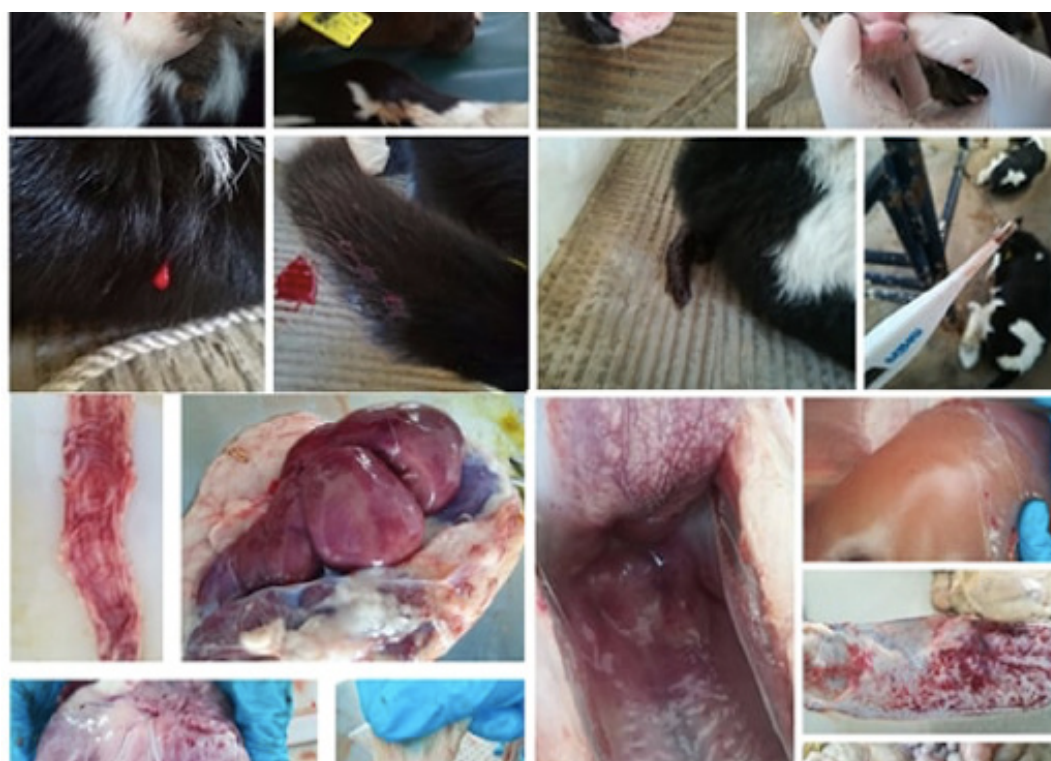


Figure 1. Abnormal bleeding symptoms and necropsy findings of first case

petechial hemorrhage on the whole body, linear bleeding in jejunum (Figure 1) and microscopically exudate with fibrin, neutrophil and blood in intestinal villus, tonsillar crypt, and pulmonary alveolus were obtained while other case could not be performed. On the other hand ELISA test and PCR were negative respect to bovine virus diarrhea virus antigen. Further more blood smear of both cases were examined for eliminating other bleeding problem, blood protozoan such as Theileriosis, toxic change of blood cells.

Discussion

Hematological and clinical findings as well as bone marrow biopsy from the femur or sternum appear to be the gold standard for BNP which is characterized by hemorrhagic diathesis of calves smaller than one month age (Sauter-Louis et al., 2012).

Clinically infected BNP-calves presented bleeding disorder (Friedrich et al., 2009; Pardon et al., 2010; Buck et al., 2001; Doll et al., 2013). Cases of BNP vary according to regional distribution clustered in regions and in veterinary practices, which might be caused by differences in relation with the usage of BVD vaccines. Besides genetic variation of dam and calves also play a role in the development of the disease (Doll et al., 2013).

Different investigation groups among several countries in Europe focused on the aetiopathogenesis of BNP (Pardon et al., 2010; Bastian, 2011; Theron, 2010) and it should not be unwise to draw conclusion that incidence of the disease remains unclear in Turkey at the national level. On the other hand during our unreported surveillance field Veterinarians noticed that they did not observe this disease frequently.

In an attempt to insight real incidence of BNP among herds in Germany, a field based study involving 243 farms in Germany, revealed that a total of 1195 calves at 1 month of their neonatal period with haemorrhagic diathesis were registered (Reichmann et al., 2016). In another previous study in Germany involving 56 cases submitted for necropsy revealed depletion of bone marrow cells walong with aplastic pancytopenia (Kappe et al., 2010). Available thrombocytopenia has been proposed as major pathophysiology of this syndrome.

In the present study although complete blood count was one of the focus of etiological research, we couldn't make blood count analysis due to technical problem. Another limitation of the study is that bone marrow cytology was not evident as re-

jected by the owner. On the other hand for the differential diagnosis blood smear was evaluated aspect of the blood protozoan such as Theileriosis, Babesiosis and toxic change of blood cells. Moreover ELISA test and PCR were negative respect to bovine virus diarrhea virus antigen that is one of the potential cause of bleeding in neonatal calf. Some toxic plants [rye grass (*Lolium* spp.), field melilot (*Melilotus officinalis*), bracken fern (*Pteridium aquilinum*)] caused hemolysis in cattle (Baily, 1978) were ruled out because calves were fed only milk and they were kept individual calf pens.

Available evidence for the first case (lower PCV, and elevated PT, APTT and FIB values along with histopathology) and for the second case (bleeding after injection and PT, APTT and FIB values) allowed us to make a suspected diagnosis of BNP.

References

- Assad A., Amann B., Friedrich A., Deeg C. A. (2012). Immunophenotyping and characterization of BNP colostrum revealed pathogenic alloantibodies of IgG1 subclass with specificity to platelets, granulocytes and monocytes of all maturation stages. *Vet Immunol Immunopathol*, 147: 25–34.
- Baily E. M.Jr: (1978). Physiologic responses of livestock to toxic plants. *J Range Manag* 31:343–347.
- Bastian M. (2011). Bovine Neonatal Pancytopenia: is this alloimmune syndrome caused by vaccine-induced alloreactive antibodies? *Vaccine*, 29(32): 5267-5275.
- Bell C. R., Rocchi M. S., Dagleish M. P., et al. (2013). Reproduction of bovine neonatal pancytopenia (BNP) by feeding pooled colostrum reveals variable alloantibody damage to different haematopoietic lineages. *Vet Immunol Immunopathol*. 151: 303–314.
- Bernier G. V., Fecteau G., Nichols S. (2011). Presumptive bovine neonatal pancytopenia in a Holstein calf in Quebec. *Can Vet J*. 52: 788–790.
- Bridger P. S., Bauerfeind R., Wenzel L., et al. (2011). Detection of colostrum-derived alloantibodies in calves with bovine neonatal pancytopenia. *Vet Immunol Immunopathol*. 141: 1–10.
- Buck B. C., Ulrich R., Kuiper, H., et al. (2001). Bovine neonatal pancytopenia in German Holstein calves. *Berl Munch Tierarztl Wochenschr*, 124(7-8): 329-336.
- Cooper C. (2012). Potential link between the development of a bleeding syndrome in young calves and

the consumption of colostrum from cows vaccinated with a killed bovine viral diarrhea vaccine. *Can Vet J*, 53: 143.

Demasius W., Weikard R., Kromik A., et al. (2014). Bovine neonatal pancytopenia (BNP): novel insights into the incidence, vaccination-associated epidemiological factors and a potential genetic predisposition for clinical and subclinical cases. *Res Vet Sci*, 96(3): 537-542.

Doll K., Wenzel L., Francke J., et al. (2013). Bovine neonatal pancytopenia- history of an exceptional disease. Part 2: Epidemiology, etiopathogenesis, therapy and prevention. *Bovine Neonatale Pancytopenie – Geschichte einer außergewöhnlichen Krankheit - Teil 2: Epidemiologie, Ätiopathogenese, Therapie und Prophylaxe. Praktische Tierarzt*, 94(5): 436-443.

Friedrich A., Buttner M., Rademacher G., et al. (2011). Ingestion of colostrum from specific cows induces bovine neonatal pancytopenia (BNP) in some calves. *BMC Vet Res*, 7: 10.

Friedrich A., Rademacher G., Weber B. K., et al. (2009). Increase in the incidence of a bleeding disorder in young calves due to bone marrow damage. *Tieraerztliche Umschau*, 64(10): 423-431.

Kappe E. C., Halami M.Y., Schade B., et al. (2010). Bone marrow depletion with haemorrhagic diathesis in calves in Germany: characterization of the disease and preliminary investigations on its aetiology. *Berl Munch Tierarztl Wochenschr*, 123(1-2): 31-41.

Kasonta R., Sauter-Louis C., et al. (2012). Effect of the vaccination scheme on PregSure® BVD induced alloreactivity and the incidence of Bovine Neonatal Pancytopenia. *Vaccine*, 30(47): 6649-6655.

Krappmann K., Weikard R., Gerst S., Wolf C., Kühn C. A. (2011). Genetic predisposition for bovine neonatal pancytopenia is not due to mutations in coagulation factor XI. *Vet J*, 190(2): 225-229.

Lambton S. L., Colloff A. D., Smith R. P., et al. (2012). Factors associated with bovine neonatal pancytopenia (BNP) in calves: a case-control study. *PLoS ONE*, 7: 34183.

Nguyen F., Guatteo R., Cesbron N., et al. (2010). Spontaneous Bleeding Syndrome in Neonatal Calves: Description of 12 Cases in France. *J Comp Pathol*, 143: 323.

Pardon B., Steukers L., Dierick J., et al. (2010). Haemorrhagic diathesis in neonatal calves: an emerging syndrome in Europe. *Transbound Emerg Dis*, 57(3): 135-146.

Pardon B., Stuyven E., Stuyvaert S., et al. (2011). Sera from dams of calves with bovine neonatal pancytopenia contain alloimmune antibodies directed against calf leukocytes. *Vet Immunol Immunopathol*, 141: 293–300.

Penny C. D., Bell C., Morrison L., Howie F., Willoughby K. (2009). Pancytopenia and haemorrhage in young beef calves. *Vet Rec*, 164(24):

Reichmann F., Pfitzner A., Rademacher G., et al. (2016). Incidence of bovine neonatal pancytopenia in 243 farms in Germany. *BMC Vet Res*, 12(1): 220.

Sauter-Louis C., Carlin A., Friedrich A., et al. (2012). Case control study to investigate risk factors for bovine neonatal pancytopenia (BNP) in young calves in southern Germany. *Prev Vet Med*, 105: 49–58.

Schroter P., Kuiper H., Holsteg M., et al. (2011). Reproducibility of bovine neonatal pancytopenia (BNP) via the application of colostrum. *Berl Munch Tierarztl Wochenschr*, 124: 390– 400.

Theron L. (2010). Neonatal pancytopenia: A new disease. (Les nouveaux défis et enjeux du vétérinaire rural au xxi^e siècle). *Point Vétérinaire*, 41: 79-85.